

# Gamma Knife vs. CyberKnife

by S. Christopher Hoffelt, MD

The procedure called “stereotactic radiosurgery” (SRS) is based on a simple concept. A series of radiation beams converges on a target from various angles (Figure 1). With proper planning, a high dose of radiation is given to a target, usually a tumor, with minimal dose to the surrounding tissue. Ideally this dosage results in destruction of the tumor while sparing function of crucial organs or tissues adjacent to the treatment area, such as the optic nerve or brainstem.

For nearly 100 years, this use of “cross-firing” beam techniques has evolved to allow treatment for both intracranial and extracranial sites. The most widely accepted use for SRS is still for intracranial disease. SRS is now a standard option for many malignant and benign lesions of the brain, as well as some functional conditions (Table 1).

Arguably the best known stereotactic radiosurgery unit is the Gamma Knife®, manufactured by Elekta. The first Gamma Knife unit in North America was installed at the University of Pittsburgh Medical Center in 1987 (Figure 2). As SRS has become an accepted standard for malignant and benign conditions, the Gamma Knife and other SRS systems have become more affordable. Hence, the technology has expanded beyond primarily university hospitals into private hospitals and freestanding centers.


The CyberKnife® is one noteworthy example of these “newer” systems, and resembles the Gamma Knife in more than just half its name. [And despite the name—stereotactic radiosurgery is “knifeless” surgery.] Both systems can effectively and accurately perform SRS for intracranial lesions. The CyberKnife differs from the Gamma Knife by employing real-time X-ray images to guide treatment; and as a result has expanded SRS to sites outside the brain. A basic understanding of both the Gamma Knife and CyberKnife is crucial for any institution to evaluate the potential for acquiring and supporting this technology.

## How Gamma Knife Works

Accuracy of the Gamma Knife is achieved by fixation of the patient’s skull to the treatment table by use of a fixed head frame (see Figure 2). A Gamma Knife treatment begins with placement of this head frame, usually by a neurosurgeon, on the morning of treatment. After local anesthetic is applied, four screws are used to tightly secure a rigid metal frame to the patient’s skull. Once the frame is properly secured, the patient is brought to the CT scanner and fixed to the scanning table in a supine position. A CT scan is acquired for treatment planning, and the patient is then released from the table and awaits treatment.

The treatment planning process begins as a cooperative effort between neurosurgeon, radiation oncologist, and physicist. The crucial first step is the delineation of the target and nearby critical tissues. These structures must be outlined by hand on the planning CT scan. In many cases, the CT images alone suffice. If necessary, clearer images from an MRI, done within 1-2 weeks prior to treatment, can be fused to the CT to allow more accurate contouring. When complete, radiation dose delivery is planned by placing one or more isocenters. Each isocenter represents a point at which all of the beams will converge for a certain amount of time (see Figure 3). The result is a high radiation dose around the isocenter with a sharp fall-off in the surrounding tissue. Spherical lesions require a single isocenter, while irregular shapes require multiple isocenters adjacent to one another to conform to the desired shape. Beam size can also be adjusted to achieve necessary shape—the Gamma Knife has circular collimators of 4, 8, 14, and 18 millimeters that can be used interchangeably.

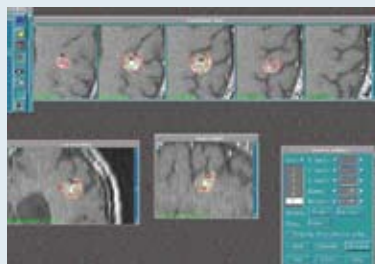
When planning is complete, the patient is placed supine on the Gamma Knife table and the head frame is fixed to the unit. The position of the head frame is adjusted with a series of dials such that the target is at the center of



**Figure 1: Schematic of stereotactic radiosurgery with the Gamma Knife®**



**Figure 2: The Gamma Knife® uses a light-weight head frame, which is affixed to the patient, for immobilization.**



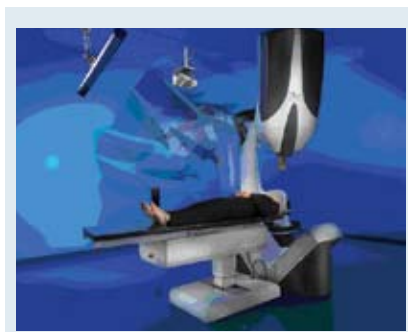
**Figure 3: A typical Gamma Knife® treatment plan. Yellow demarcates the prescribed dose; four isocenters are used in this plan.**

the beam, as defined by the plan. The most recent Gamma Knife unit makes these adjustments automatically. The patient is then monitored from outside the room while treatment is given, usually 30 to 90 minutes. Usually a single operator is necessary to assure safe treatment delivery and patient monitoring, most often a physicist or radiation therapist.

It is not practical to leave the head frame in place for more than one or two days, so treatments with the Gamma Knife are generally limited to a single dose. The patient typically remains hospitalized while the head frame is in place. This dosage is appropriate for most standard applications. The time allowed for treatment planning is limited but usually poses no difficulty for experienced users.

### How CyberKnife Works

The CyberKnife is another capable SRS system for treating brain lesions, but its design has expanded SRS for lesions anywhere in the body, including structures that move with respiration. While the Gamma Knife treats



**Figure 4: The CyberKnife® uses a plastic mask for patient immobilization.**

with multiple beams simultaneously, the CyberKnife uses a single high-energy photon beam fixed to a robot arm. The arm moves the beam to different positions during the course of treatment, all converging in the treatment area (see Figure 4). Unlike the Gamma Knife, a head frame is not required for sub-millimeter accuracy. Instead, the patient is fixed to the treatment table with a firm plastic mask, and the robot is guided by a series of X-ray images of the skull taken during

treatment. The position of the skull is updated real-time, and the robot adjusts the beam to account for any skull movement. Thus, SRS for cranial lesions is non-invasive, and recently updated CyberKnife planning software allows treatment of some spine lesions using image guidance alone, without fiducial markers. Some CyberKnife centers are treating selected patients routinely with this method, though experience is still limited.

For most treatments outside the skull and spine, the CyberKnife requires more than just bone anatomy to guide the beam position. These areas, especially lesions that move with respiration, require the placement of gold fiducials near or within the target. Fiducials are usually placed as a simple outpatient procedure, similar to a needle biopsy. X-ray images capture the position of these markers and guide the robot during treatment to correct for movement. For targets that move with respiration, the CyberKnife can correlate the beam position with the pattern of respiration and adjust accordingly. This feature is useful for treating tumors in the lung or liver.

The design of the CyberKnife results in a different treatment process for the patient. The fiducials, if necessary, must be implanted several days before planning images can be acquired. Images are then acquired as an outpatient, with one or two visits for a CT scan and MRI if necessary. Planning is performed while the patient is at home, without the time pressure associated with the head or body frame. The planning is typically a joint effort between radiation oncologist, surgeon, and physicist, usually within one day. Complex cases may take several iterations, occasionally requiring two or more days. Treatments are usually delivered by a radiation therapist, with physicians present for the initiation of treatment.

### CyberKnife vs. Gamma Knife

A fair comparison regarding CyberKnife and Gamma Knife must be limited to their ability to treat lesions in the head, as the latter cannot treat extracranial sites. The need for precision in SRS treatments within or adjacent

#### TABLE 1: Common Conditions for Which Stereotactic Radiosurgery is Indicated

##### *Neoplasms*

Brain metastases  
Acoustic neuroma/Vestibular schwannoma  
Meningioma  
Pituitary adenoma  
Glioma/astrocytoma  
Chordoma/Chondrosarcoma  
Craniopharyngioma  
Hemangioblastoma  
Ocular melanoma  
Nasopharynx carcinoma  
Glomus jugulare tumors

##### *Vascular Disorders of the Brain*

Arteriovenous malformations (AVM)  
Arteriovenous fistulas (AVF)  
Cavernous malformations

##### *Other Disorders*

Trigeminal neuralgia (tic douloureux) (painful condition of the face)

# The ability to treat any body site distinguishes CyberKnife from the Gamma Knife.

to sensitive brain tissues is obvious, hence accuracy is a reasonable first point of discussion. Both the Gamma Knife and CyberKnife employ regularly scheduled, strict quality assurance measurements, including film, to simulate a treatment. For both, the accuracy of treatment delivery can usually be confirmed to within less than 0.5 mm. Other sources of error are unaccounted for in these measurements. The CyberKnife real-time image capture may generate an additional 0.5 mm error.<sup>1</sup> The Gamma Knife head frame is not entirely rigid, and may account for less than 0.5 mm up to 1.7 mm inaccuracy.<sup>2,3</sup> Regardless of these potential sources of error, most users will agree that accuracy of both units is more than adequate for treatment of appropriate intracranial lesions.

Clinical efficacy is a second important point of discussion. For the numerous applications listed in Table 1, use of the Gamma Knife has been arguably the dominant resource for published literature regarding efficacy of SRS for the past 30 years. Literature specific to the newer CyberKnife is far less abundant but continues to emerge. It is fair to consider CyberKnife efficacy similar to most linear accelerator-based radiosurgery system using similar beam energies. These systems have also contributed substantially to the SRS literature for intracranial lesions, establishing their use as standard for appropriate patients.

The ability to treat any body site distinguishes CyberKnife from the Gamma Knife. Tomotherapy, Trilogy, Novalis, and Elekta Body Frame are other systems sharing this capability. Extracranial radiosurgery has enormous potential as a standard treatment option but is still largely an emerging application. Data, yet limited, have demonstrated promising results for certain tumors of the liver,<sup>4-6</sup> lung,<sup>7-9</sup> and spine,<sup>10-11</sup> and for radiation-resistant histologies. Results from larger published studies, including RTOG 0236, a clinical trial for early stage lung cancer, are expected within a few years.

Other important considerations exist. A reported but uncommon limitation of the Gamma Knife or any frame-based SRS system is the ability to treat peripheral brain or base-of-skull lesions. This situation can result in a collision of the frame or patient with the hardware if the target location extends beyond the treatable volume. The small size of the Gamma Knife collimators may be advantageous in sparing dose to critical tissues,<sup>12</sup> but can create difficulty in treating lesions larger than 3-4 cm. Errors in the CyberKnife or other image-guided SRS systems may result from image resolution and registration, the quality of the planning images, and errors in couch and robot arm positioning.

Cost is certainly an important consideration for any institution. Formal written estimates for the unit cost

obtained from each company can vary by region but are comparable, ranging from \$3.4 to \$4 million dollars. It is also important to consider installation, physics, and therapist training and support, and maintenance costs for these units. Because these costs also vary by region, it is important to discuss these factors with their respective companies.

The long, established history of Gamma Knife certainly contributed to the development of the CyberKnife and other intracranial and extracranial SRS systems. Direct, formal clinical comparisons will likely be available in the future, as more data for intracranial and extracranial applications emerge. While costly, both units are practical and effective for appropriate patients. ■

---

*S. Christopher Hoffelt, MD, is medical director of Radiation Oncology at Southwest Washington Medical Center and assistant professor of Radiation Oncology at Oregon Health Sciences University in Portland, Ore.*

## References

- <sup>1</sup>Chang SD, et al. An analysis of the accuracy of the CyberKnife: a robotic frameless stereotactic radiosurgical system. *Neurosurg.* 2003;52:140-147.
- <sup>2</sup>Maciunas RJ, et al. An independent application accuracy evaluation of stereotactic frame systems. *Stereotact Funct Neurosurg.* 1992;58(1-4):103-7.
- <sup>3</sup>Rohlfing T, et al. Effect of changing patient position from supine to prone on the accuracy of a Brown-Roberts-Wells stereotactic head frame system. *Neurosurg.* 2003 Mar;52(3):610-8; discussion 617-8.
- <sup>4</sup>Sampson MC, et al. Hypofractionated stereotactic body radiation therapy for liver metastases. Proceedings of 47<sup>th</sup> Annual Meeting of ASTRO S215, October 2005.
- <sup>5</sup>Hefarth KK, et al. Stereotactic irradiation of liver metastases. *Radiologe.* 2001. Jan;41(1):64-68.
- <sup>6</sup>Constantino T, et al. Extra-cranial stereotactic radiosurgery for hepatoma. Proceedings of the 45<sup>th</sup> Annual Meeting of ASTRO S281 October 2003.
- <sup>7</sup>Uematsu M, et al. CT-guided stereotactic radiation therapy for stage I non-small cell lung cancer: 8-year results of 50 initial patients. Annual Meeting of ASTRO S281 October 2003.
- <sup>8</sup>Wulf J, et al. Stereotactic radiotherapy of targets in the lung and liver. *Strahlenther Onkol.* 2001;Dec.177(12):645-55.
- <sup>9</sup>Nagata Y, et al. Clinical outcomes of phase I/II study of 48 Gy in 4 fractions for primary lung cancer using a stereotactic body frame. Proceedings of the 46<sup>th</sup> Annual Meeting of ASTRO S285 October 2004.
- <sup>10</sup>Degan JW, et al. Cyberknife stereotactic radiosurgical treatment of spinal tumors for pain control and quality of life. *J Neurosurg Spine.* 2005 May;2(5):540-549.
- <sup>11</sup>Benzil DL, et al. Safety and efficacy of stereotactic radiosurgery for tumors of the spine. *J Neurosurg.* 2004 Nov; 101 Suppl 3:413-418.
- <sup>12</sup>Petti PL, et al. Peripheral doses in CyberKnife radiosurgery. *Medical Physics.* June 2006 33(6):1770-1779.